



info@aeacarizona.com

Address: 7 E. Palo Verde St.,
Suite #1
Gilbert, AZ 85296

<http://www.aeacarizona.com>

Phone: (480) 706-8478
Fax: (480) 393-3915
Emergencies: Page (602) 351-1850

Adrenal Gland Disease in Ferrets

Adrenal Gland

- Endocrine gland that sits above the kidneys
- Divided into a cortex and a medulla
- Main responsibility is to regulate the stress response through the synthesis of corticosteroids (i.e. cortisol) and catecholamines (i.e. adrenaline)

Adrenal Cortex

Adrenal cortex is divided into 3 zones:

- Zona glomerulosa: Main site for production of mineralocorticoids, namely aldosterone
- Zona fasciculata: Mainly responsible for producing glucocorticoids (cortisol)
- Zona reticularis: Produces androgens (estrogen, testosterone)

Stages of Adrenocortical Disease in Ferrets

1. Adrenal hyperplasia:
 - Increase in the size of the adrenal cells resulting in an increase in the amount of hormones produced by the adrenal cortex
2. Adrenal adenoma:
 - Benign tumor arising from the cortex of the adrenal gland
3. Adenocarcinoma:
 - Malignant (cancerous) tumor arising from the cortex of the adrenal gland

Causes of Adrenocortical disease

- The exact causes of the changes in adrenal glands that lead to adrenocortical disease is unknown
- Several possible hypotheses:
 - Early age of sterilization (typically between 4-6 weeks of age)
 - Prolonged photoperiods
 - Genetic component due to inbreeding
 - Diet

Signs of Adrenocortical Disease



info@aeacarizona.com

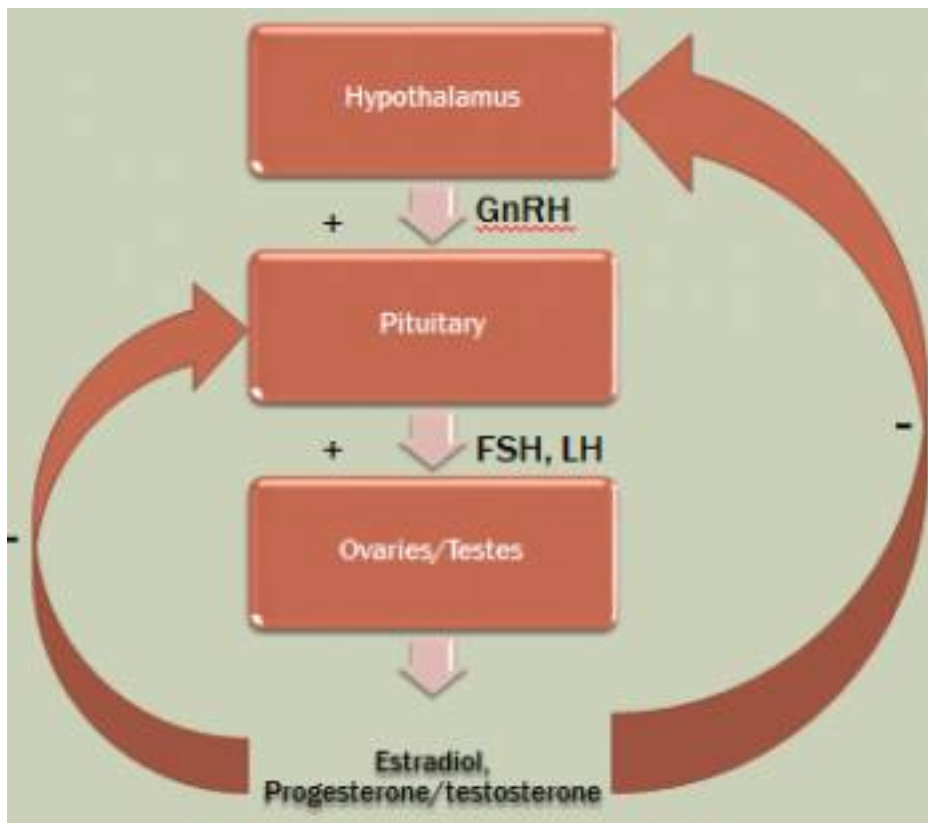
Address: 7 E. Palo Verde St.,
Suite #1
Gilbert, AZ 85296

<http://www.aeacarizona.com>

Phone: (480) 706-8478
Fax: (480) 393-3915
Emergencies: Page (602) 351-1850

- Hair loss (alopecia)
- Vulva swelling in females
- Enlarged prostate in males and urethral obstruction
- Increased sexual aggression (males often grab and drag females by the nape of the neck)
- Muscle atrophy
- Pruritus (itchiness)
- Thinning of the skin
- Lethargy
- Enlarged adrenal glands

GnRH Feedback Loop



Negative Feedback of GnRH

- The absence of normal gonadal secretion of estrogen and other androgens in neutered/spayed ferrets results in a lack of negative feedback on the hypothalamus,



info@aeacarizona.com

Address: 7 E. Palo Verde St.,
Suite #1
Gilbert, AZ 85296

<http://www.aeacarizona.com>

Phone: (480) 706-8478
Fax: (480) 393-3915
Emergencies: Page (602) 351-1850

causing continuous secretion of GnRH and continuous stimulation of the hormonal cascade

- The continuously secreted GnRH in turn stimulates the pituitary gland, which consequently secretes Luteinizing Hormone (LH) and Follicle Stimulating Hormone (FSH)
- If ferrets incorporate gonadal cells into the adrenal gland, LH and FSH will stimulate an increased secretion of sex hormones by the adrenal gland, thus resulting in the adrenal gland changes that result in adrenocortical disease

Photoperiod

- Ferrets are descended from the European polecat, who inhabit a region of the world where there are long periods of darkness
- Ferrets in the United States are exposed to less definitive seasonal photoperiods
- Ferrets kept at light cycles longer than 8 hours have been reported to have increased GnRH and LH production, increasing the risk of adrenal disease

Melatonin

- Melatonin's exact mechanism of action is poorly understood, but it does inhibit GnRH secretion from the hypothalamus
- Melatonin is produced by the pineal gland within the brain during dark hours
- It is thought that ferrets experiencing artificially prolonged photoperiods may become deficient in melatonin, increasing their likelihood of development of adrenal disease
 - Keeping your ferret in a dark room will increase their melatonin production and reduce the risk of adrenal disease development

Treatment Options for Adrenal Disease

- Ferretonin
 - Ferretonin is a melatonin implant about the size of a grain of rice that is injected under the skin of your ferret between the shoulder blades
 - Melatonin is a natural inhibitor of GnRH
 - By inhibiting GnRH, the production of LH and FSH is reduced, preventing their negative effect on the adrenal gland
 - The implant is broken down by the body and eliminated, and must be administered repeatedly with the return of adrenal disease signs (i.e. hair loss)
- Lupron
 - Lupron is a long-acting GnRH analog
 - Can relieve clinical symptoms of adrenal disease for 2-8 months



info@aeacarizona.com

Address: 7 E. Palo Verde St.,
Suite #1
Gilbert, AZ 85296

<http://www.aeacarizona.com>

Phone: (480) 706-8478
Fax: (480) 393-3915
Emergencies: Page (602) 351-1850

- Administered by injection every 1 or 4 months
- Lupron functionally imitates GnRH stimulating the release of FSH and LH from the pituitary gland and ultimately the production of estrogen and testosterone, which negatively inhibits any further release of GnRH from the hypothalamus.
- Consequently, Lupron in the long-term will decrease the production of the sex hormones that facilitate adrenal disease
- Deslorelin
 - Deslorelin is a GnRH-agonist that stops the production of sex hormones (testosterone and estrogen)
 - Deslorelin is an implant that is injected under the skin of the ferret between the shoulder blades, allowing the continuous, low-level release of the drug
 - Unlike Lupron and Ferretonin, Deslorelin only has to be administered every 18 months to 2 years
 - Deslorelin works by inhibiting the synthesis and release of LH and FSH by the pituitary gland, decreasing the effect of these hormones on the adrenal gland
- Surgery
 - Surgical removal of the adrenal gland is the only definitive treatment for adrenal disease but is performed only if the other treatment approaches are no longer effective
 - Removal of the right adrenal gland is considered more challenging because it is found attached to the caudal vena cava (great vessel which transports the bulk of deoxygenated blood back to the heart)
 - Removal often results in significant blood loss
 - Most veterinarians in turn debulk the majority of the right adrenal gland
 - This often leaves hormone-secreting tissue and the tumor in turn often continues to grow and produce clinical signs
- The use of drugs (mitotane, ketoconazole, or streptozocin) currently utilized to treat hyperadrenocorticism in humans, dogs, and cats is unsuccessful in ferrets as it targets a different layer in the adrenal cortex that is not affected with ferret adrenal disease

New Surgical Option Used at AEAC

- 2-surgery technique
- The first surgery involves the placement of a 5-mm ameroid constrictor ring just distal to the adrenal gland around the caudal vena cava
 - Ameroid constrictor rings are stainless steel rings that have a nearly closed C-shape
 - The inner part of the ring is a synthetic colloid (ameroid) that swells slowly as it contacts abdominal fluid and stimulates the inflammatory process



info@aeacarizona.com

Address: 7 E. Palo Verde St.,
Suite #1
Gilbert, AZ 85296

<http://www.aeacarizona.com>

Phone: (480) 706-8478
Fax: (480) 393-3915
Emergencies: Page (602) 351-1850

- The C-shape forms a complete ring during surgery when the steel key is seeded between the ameroid and steel wall
- The second surgery is performed 1-3 months later in order to allow collateral circulation to develop
- During the second surgery, the ameroid constrictor ring is removed, as well as a portion of the caudal vena cava and associated adrenal gland and the caudate process of the liver
- Thus far, there has been 8 successful cases out of 9 procedures performed with no mortality